TRAJECTORIES OF WHITE MATTER DEGENERATION IN FRONTOTEMPORAL DEMENTIA: NEW INSIGHTS USING FIXEL-BASED ANALYSIS

Ramon Landin-Romero[1,2*], Halle Quang[1,2], Sophie Matis[1,2] , Arkiev D'Souza[2,4], Fernando Calamante[2,4], Olivier Piguet[2,3]

[1]Sydney School of Health Science, The University of Sydney, NSW, Australia
[2]Brain & Mind Centre, The University of Sydney, Sydney, Australia
[3]School of Psychology, The University of Sydney, Sydney, Australia
[4]School of Biomedical Engineering, The University of Sydney, Sydney, Australia

ABSTRACT

Neuropathology in frontotemporal dementia (FTD) shows 'prion-like' propagation along white matter tracts. Mapping upstream white matter trajectories *in-vivo* will improve understanding of disease mechanisms in FTD, but longitudinal white matter studies are rare. Here, we develop a new method to investigate white matter degeneration based on fixel-based analysis in 60 FTD patients and 30 matched heathy controls. Changes in white matter fibre density and cross-section were examined with spatiotemporal linear mixed effects models. We show (i) more extensive and (ii) new sites of white matter degeneration in FTD, with syndrome-specific effects and improved biological interpretability. Our findings inform better models of disease staging in FTD and provide useful targets for drug interventions.

BACKGROUND

Structural brain connectivity (i.e., white matter) is an early marker of clinical severity in FTD and a good proxy of underlying protein pathology

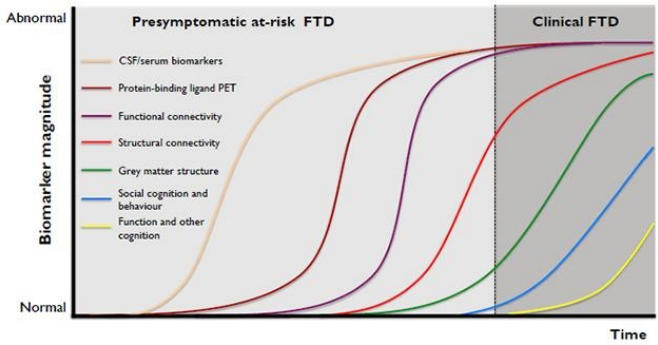

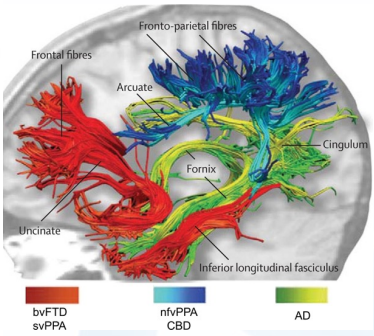

Previous research have shown gross white matter atrophy in the 3 main FTD presentations; behavioural-variant FTD (bvFTD, red tracts), progressive non-fluent aphasia (PNFA, blue tracts) and semantic dementia (SD, red tracts)

Accurate modelling of white changes trajectories **over time** and *in-vivo* is needed to inform disease staging in FTD

Current understanding is limited by outdated MRI diffusion tensor methods[1] (DTI) and lack of longitudinal studies[2]

Fixel-based analysis (FBA)[3] is a new technique that provides increase sensitivity to detect subtle WM changes in anatomically complex regions (e.g., multiple crossing fibers)

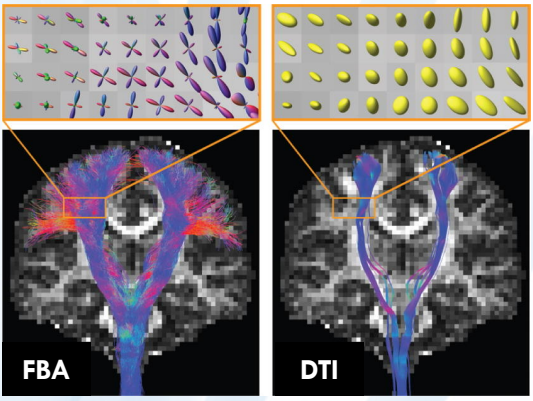

Here we develop a combination of FBA and spatiotemporal linear mixed effect modelling to map progressive white matter atrophy in FTD with improved sensitivity/specificity and biological interpretability

METHODS

Sixty FTD patients (23 bvFTD, 15 PNFA and 22 SD) age-, sex- and education-matched with 30 heathy controls

Participants underwent annual clinical and high-resolution MRI (median 2 years; range 1-6 years)

(a) Computation of 3 measures of WM fibre integrity: FD, FC and FDC
(b) Fibre tracts are colour-coded to indicate direction of WM bundles: (red: left/right; blue: superior/inferior; green: anterior/posterior)

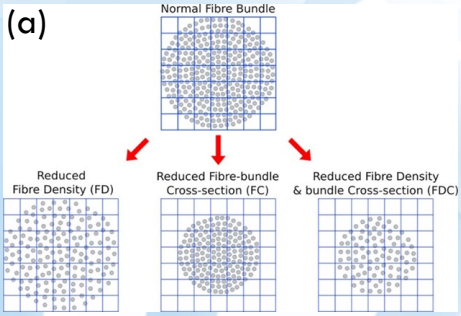

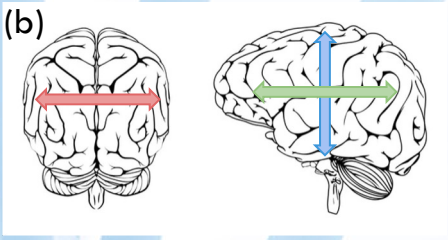

Analysis pipeline based on FBA in implemented in MRtrix3 software

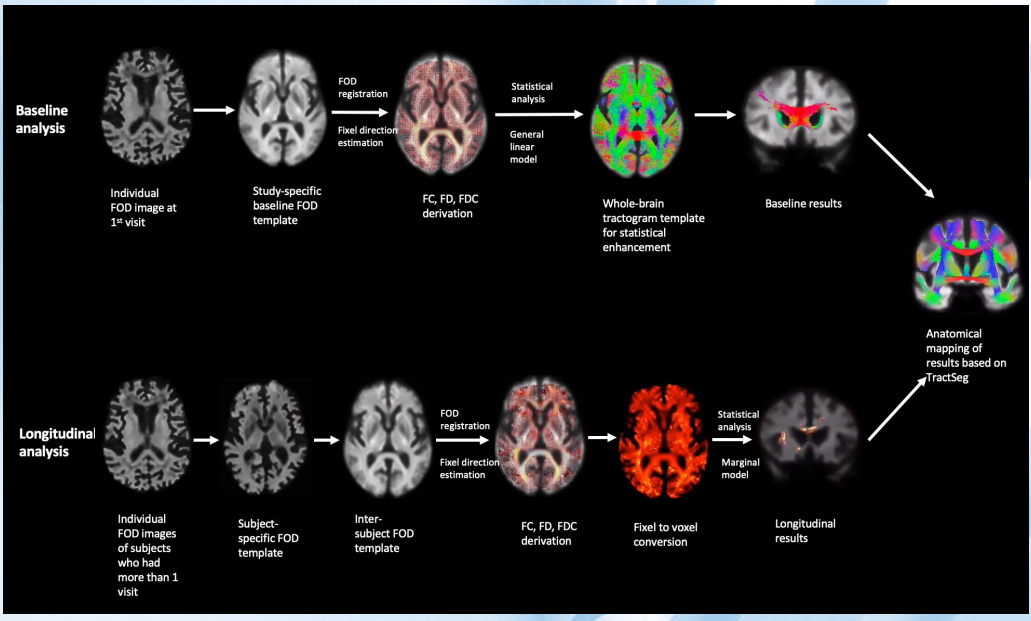

RESULTS

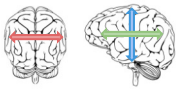

Baseline atrophy in FTD vs healthy controls. White matter changes in FTD patients expressed as % decrease in white matter fibre density and cross-section (FDC) relative to controls

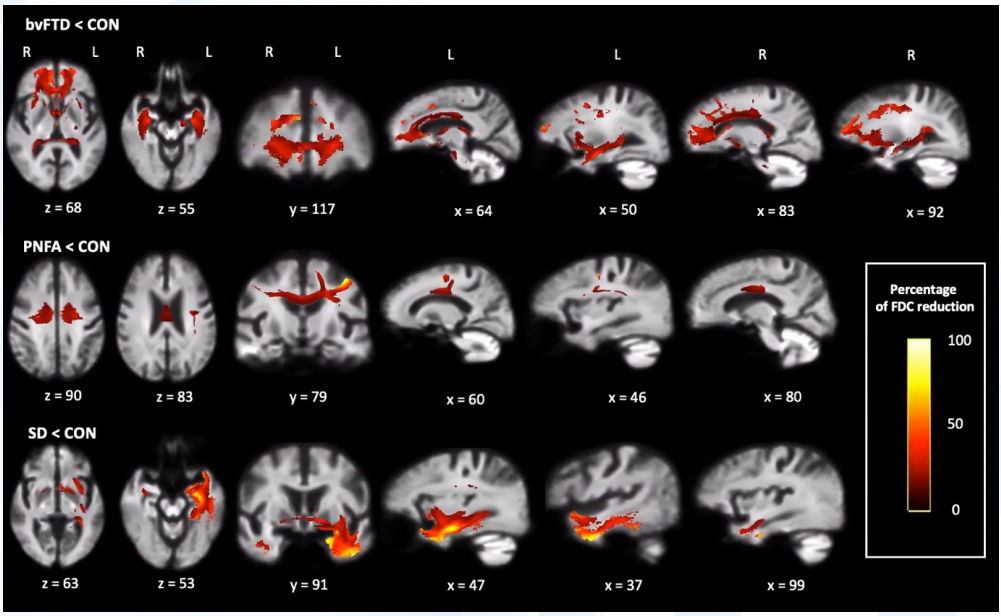

Baseline and progressive atrophy in bvFTD. WM atrophy (i.e., FDC decrease) extends posteriorly over time, encroaching in tracts connecting subcortical and motor-associations regions

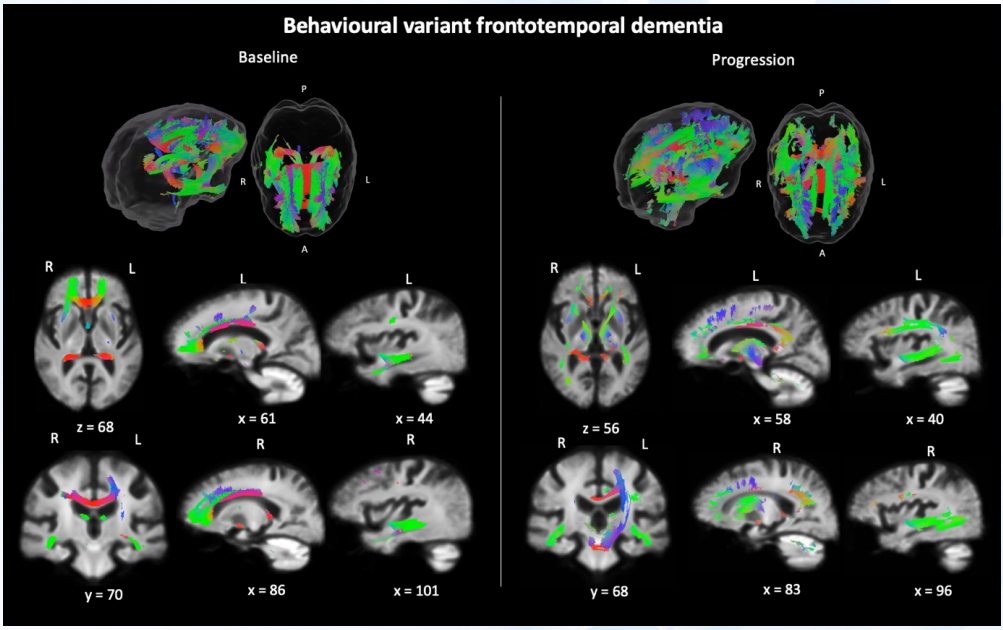

RESULTS

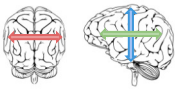

Baseline and progressive atrophy in PNFA. Left-lateralised baseline atrophy extends anteriorly and inferiorly, and into the contralateral hemisphere, mirroring atrophy at presentation

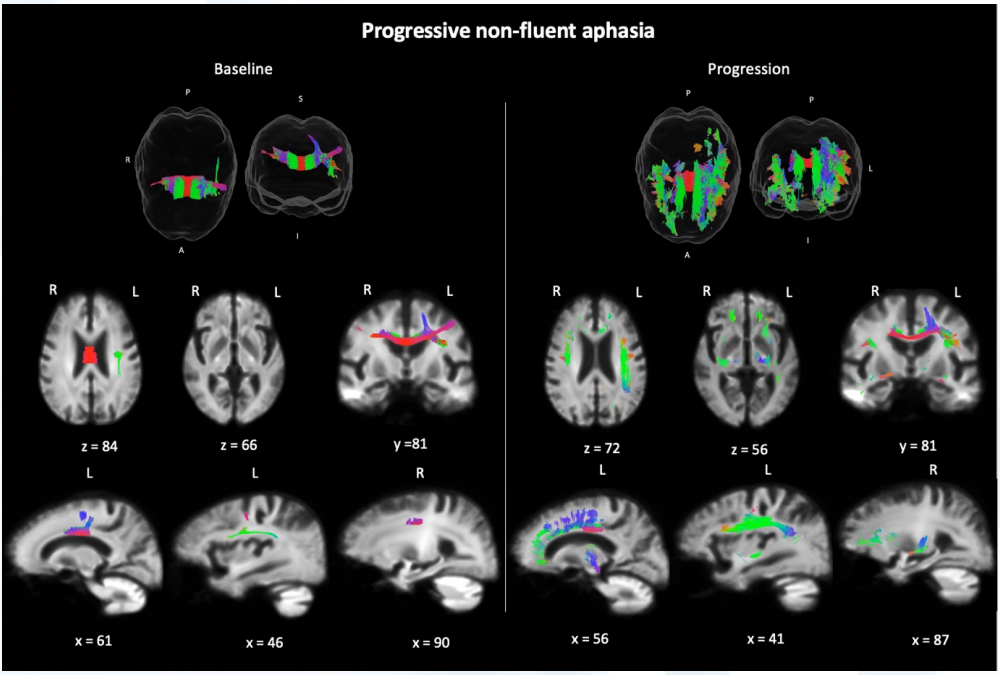

Baseline and progressive atrophy in SD. Atrophy extends posteriorly/laterally from the anterior left to right hemisphere

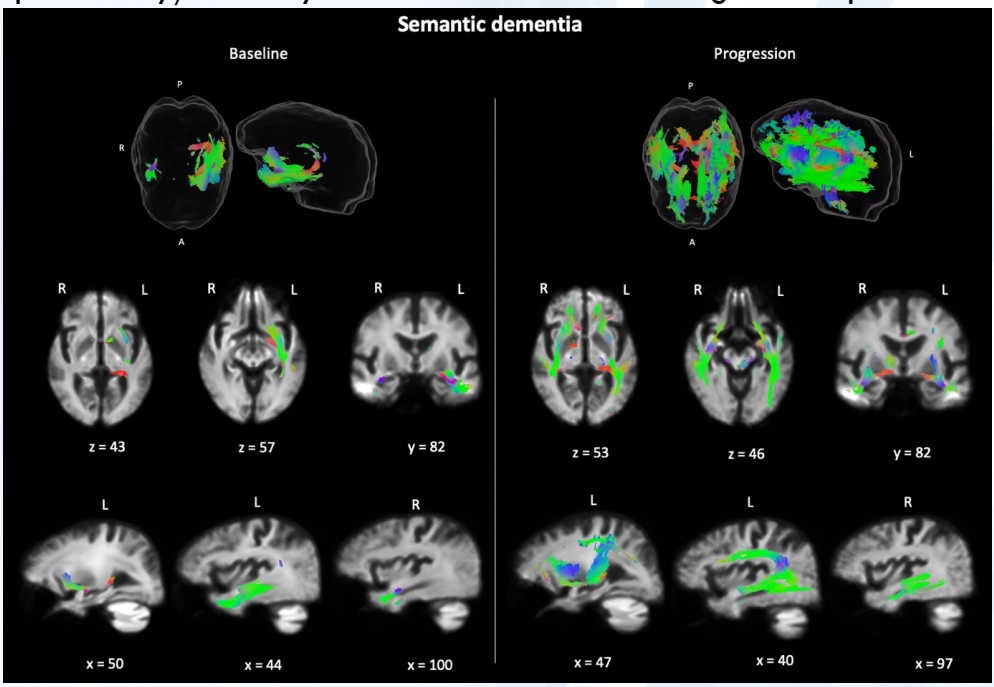

CONCLUSIONS

1. All FTD syndromes showed more extensive white matter atrophy than reported before
2. We uncovered involvement of new white matter bundles in FTD with syndrome-specificity
3. We report for the first time trajectories of white matter degeneration in FTD over the course of several years of follow-up
4. White matter atrophy spreads posteriorly and laterally towards the right hemisphere, mirroring baseline patterns across FTD syndromes
5. Our method can be used to predict consequent grey matter neurodegeneration and emergence of clinical phenotypes, with important diagnostic and disease monitoring implications
6. We provide useful biological targets associated with disease severity in FTD for patient stratification and monitoring in drug intervention trials

REFERENCES

1. Calamante F (2019). The Seven Deadly Sins of Measuring Brain Structural Connectivity Using Diffusion MRI Streamlines Fibre-Tracking. Diagnostics (Basel). 2019 Sep 6;9(3):115
2. Landin-Romero R and Piguet O. (2017) Recent advances in longitudinal structural neuroimaging of younger-onset dementias. Neurodegener Dis Manag, 2017. 7(6): p. 349-352.
3. Raffelt DA et al. (2017). Investigating white matter fibre density and morphology using fixel-based analysis. Neuroimage 1;144(Pt A):58-73

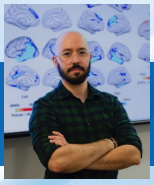

Email: ramon.landin-romero@sydney.edu.au
Twitter: @DrLandinRomero